

CASE REPORT

Rare Locations of Epidermoid Cyst: Case Reports and Review

Saibaba Mahalakshmi¹, Sateesha Reddy², T K Ramamurthy², B Shilpa²

ABSTRACT

BACKGROUND: Epidermoid cysts are benign lesions encountered throughout the body. Eighty percent of epidermoid cyst seen in ovaries and testicles, whereas in head and neck region they account for only 1.6-7.0%. 1.6% of epidermoid cysts occur in oral cavity and they account for 0.01% of all the oral cavity cysts.

CASE DETAILS: Two case reports of epidermoid cyst has been discussed. One patient reported with well defined swelling in the right lower one third of the face, another one in the upper lip. Initially the cases were diagnosed as Lipoma and salivary adenoma respectively but histologically they turned out to be epidermoid cyst. Hence, we aim at highlighting the differential diagnosis pertaining to the anatomical location. The PubMed database search made on January 2016 yielded 674 articles of epidermoid cyst in the head and neck region. In that there is only one case reported occurring in the lower one third of face. In the current report, we outline the second case of epidermoid cyst localized to the right mandibular body region without bone involvement. Another case in our report was localized in the upper lip. In the literature totally seven cases were reported till now occurring in the lip.

CONCLUSION: Although epidermoid cysts are rarely encountered in the oral cavity, the possibility that they may occur warrants the need for successful management to avoid misdiagnosis.

KEYWORDS : Epidermoid cyst, Dermoid cyst, Lower one third of face, Mandibular body, Upper lip.

DOI: <http://dx.doi.org/10.4314/ejhs.v26i6.14>

INTRODUCTION

Epidermoid cysts (EC) are benign lesions encountered anywhere in the body in areas where embryonic elements fuse together. The majority of the cases are reported in ovaries and testicles (80%); 7% reported to occur in the head and neck region, 1.6% in the oral cavity, accounting for 0.01% of all the oral cavity cysts(1-3). The commonly involved site in head and neck region is external third of the eye-brow followed by floor of the mouth (4). Rarely, cases are reported in tongue, buccalmucosa, parotid gland, lower lip and intraosseously (5). We outline two cases of epidermoid cyst: one occurring in the right mandibular body region without bone involvement, another one localized to the upper lip. The aim of the current report is to describe the differential diagnosis pertaining to the anatomic

location and also to consider these entity during diagnosis and management.

CASE 1

A 50-year old male patient reported to the outpatient department with complaint of an asymptomatic swelling in the right lower 1/3rd of the face that occurred before 4 years. Initially, the swelling was peanut-sized which gradually increased. The patient gave the history of discharge from swelling 2 years back which was paste-like mixed with blood. His past dental and medical histories were not contributory. On clinical examination, a well circumscribed, solitary, oval swelling was seen on the right mandibular body region, extending supero-inferiorly from the right corner of the mouth to the inferior border of the mandible measuring about 2.5cm and medio- laterally extending 2cms away

¹Department of Oralmedicine and radiology, Sri Siddhartha Dental College and Hospital, Sri Siddhartha Academy of Higher Education, Agalkote, Tumkur

²Department of Oralmedicine and radiology, AECS Maaruti College of Dental Sciences & Research Centre, Bangalore

Corresponding Author: Saibaba Mahalakshmi, Email: ammisaignanesh@gmail.com

from the mental protuberance to the midportion of the body of the mandible roughly measuring about 4cms in size. The skin over the swelling was stretched and shiny; the center of the swelling

showed brownish black postinflammatory pigmentation. On palpation, the swelling was nontender, smooth and soft in consistency (Figure 1a).

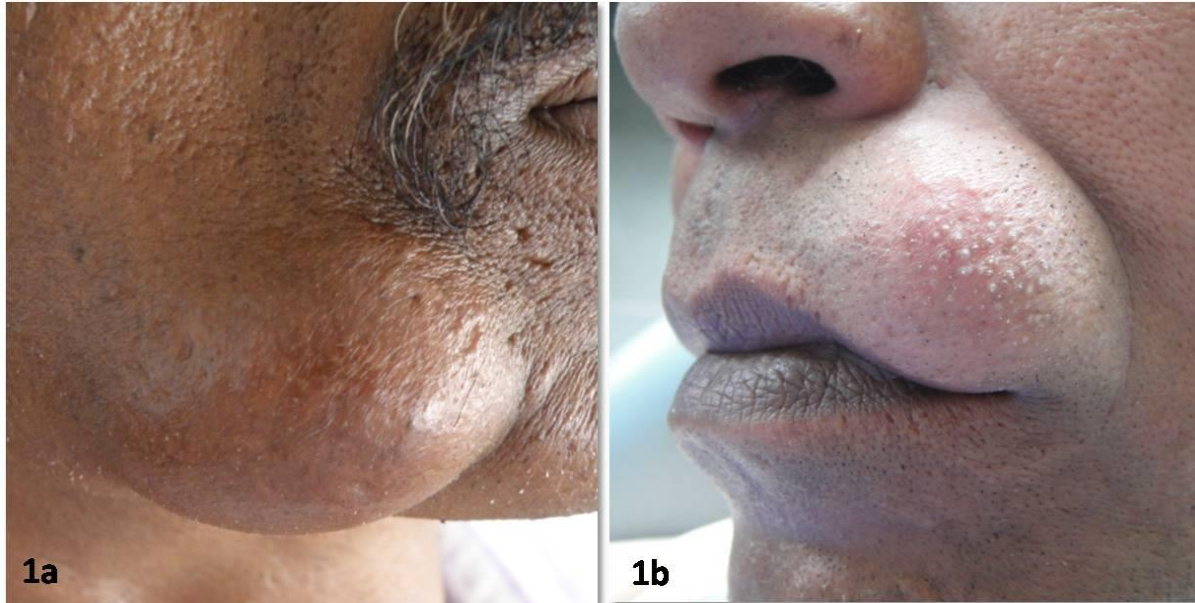

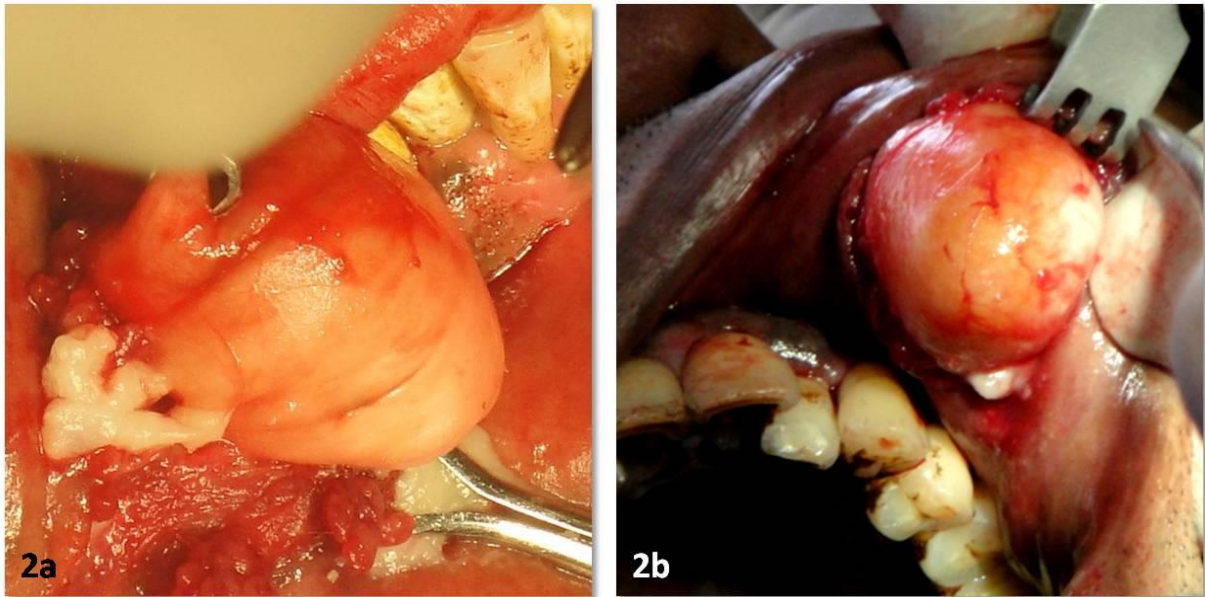
Figure 1a: Extra oral view showing the swelling of the right lower one third of the face on the body of the mandible

Figure 1b: Extra oral view showing the swelling of the left corner of the upper lip

CASE 2

A 38-year old male patient reported to the outpatient department with complaint of facial asymmetry due to swelling in the upper lip that began before 3 years. Initially, the swelling was peanut-sized which gradually increased in size. There were no associated symptoms. His past dental and medical histories were not contributory. On examination, a well circumscribed, dome shaped solitary oval swelling was seen on the left side of the upper lip, extending supero-inferiorly from the ala of the nose to the vermilion border of the lip, roughly measuring about 3cm. Antero-posteriorly extending 1cm away from the philtrum of lip to the corner of the mouth roughly measuring about 2.5cm. The skin over the swelling appeared to be stretched and shiny with erythema seen at the center (Figure 1b). On palpation, the swelling was firm, nontender, smooth and not associated with any discharge.

In both the cases, there was no evidence of cervical lymphadenopathy. Based on the history and clinical finding, the first case was diagnosed initially as lipoma and the second one as salivary adenoma. In both the cases, complete hemogram and ESR were within the normal limits. Surgical excision was done under local anesthesia. During enucleation, a thick creamy, cheese-like material oozed out due to rupture of the cystic wall in both the cases (Figures 2a and 2b). The cyst was completely enucleated and debrided carefully. Postoperatively, the patient had a mild swelling, as the spillage of cystic content acts as a fibrovascular irritant. A course of antibiotics helped in reducing the inflammation. The excised tissue was a yellowish white oval mass; case one specimen measured 4x3x3 cm in size (Figure 3a) and in case two measured 2X2 cm in size (Figure 3b).



Figures 2a and 2b: *Enucleation of the cyst intraorally, white chesy creamy material oozing out due to the rupture of cyst during exsion*

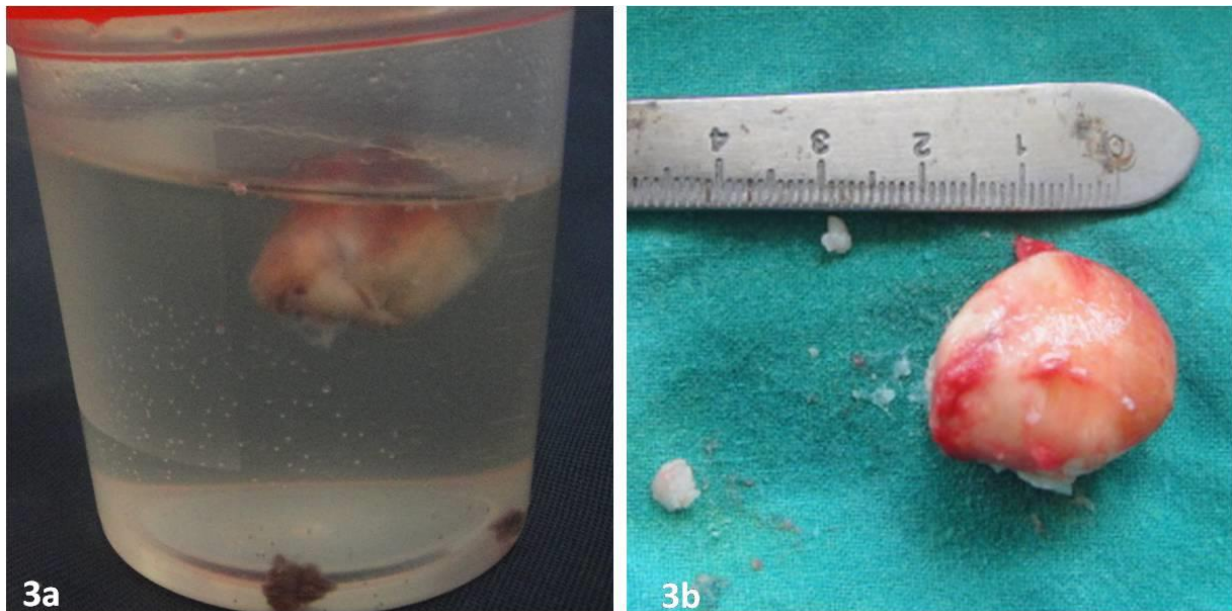
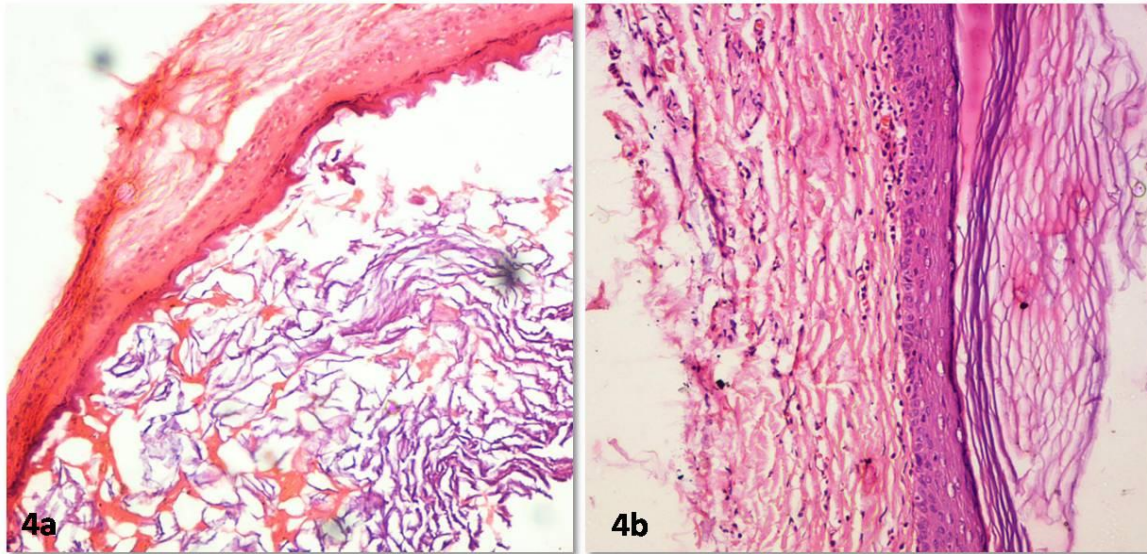


Figure 3a: *Excised specimen was yellowish white in colour measured about 4x3x3 cm in size*

Figure 3b: *Excised specimen measured 2X 2 cm in size.*

Histopathological examination in both the cases revealed a cystic cavity lined by stratified Squamous orthokeratinized epithelium of 5-7 cell layer thickness with prominent granular layer. Cystic lumen showed abundant keratin arranged in

laminar pattern. The connective tissue wall showed dense bundles of collagen fibers and blood vessels (Figures 4a and 4b). After correlating clinical and histopathological features the cases were diagnosed as epidermoid cysts.



Figures 4a and 4b: Hematoxylin & Eosin stained section shows cystic cavity lined with orthokeratinized stratified Squamous epithelium with prominent granular layer under 20x magnification

DISCUSSION

Roser was the first person to designate dermoid cyst in the floor of the mouth as epidermoid tumor (6). In the oral cavity, the floor of the mouth is the most favored site for epidermoid cyst. Rarely cases are reported involving tongue, buccal mucosa, uvula ,TMJ dermal graft . Very few casess of intraosseous (maxilla and mandible) epidermoid cyst are also reported in literature. Literature search in Pubmed showed only one case reported by Pereira-Santos D(7) occurring in the

left side of the face on the body of the mandible without any bone involvement. Hence, ours could be the second case to be reported to occur on the body of the mandible without bone involvement. There are totally seven cases of epidermoid cyst occurring on lip in the literature. Three cases out of these involved lower lip and three involved upperlip(Table 1). One of the cases reported in lip we were unable to access the complete article.

Table 1: Details of Epidermoid cyst occurring in face and lip reported in literature

Author	Year	Location
Pereira-Santos D(7)	2013	left side of the face on the body of mandible without any bone involvement
Phukan JP(8)	2014	Upper lip
Dogan F(9)	2014	Upper lip
Wang WC (10)	2005	Lower lip
Papanayotou PH (11)	1977	Lower lip
Ishikawa T (12)	1976	Lower lip
Sewerin I (13)	1974	Lip
Kuroyanagi K (14)	1973	Upper lip

EC occurs in any age group and shows preponderance between second and fourth decades of life. It is common in men than women with a

ratio of 3:1(15). EC generally presents as a painless, slow growing well circumscribed lesion. Based on the content of the cystic cavity, it may

be soft, firm or dough-like in consistency. The clinical findings in our cases were consistent with previously reported cases. our cases fulfilled the histopathological characteristics suggested by Meyer (1,3):

1. Epidermoid cysts: The cystic cavity is lined with epithelium without skin appendages.
2. Dermoid cysts: The epithelial lined cystic cavity encloses skin appendages such as hair, hair follicles, sebaceous, and sweat glands.
3. Teratoid cysts: The cystic cavity in addition to skin appendages encloses mesodermal derivatives such as bone, muscle, gastrointestinal and respiratory tissue.

Epidermoid cyst can be congenital and acquired type based on the pathogenesis. Most

researchers have reported that congenital dermoid and EC that appear in the midline are the result of entrapped ectodermal tissue of the first and the second brachial arch which fuse during third and fourth weeks in intrauterine life (3,6,16-17). Some authors suggest that they might be a variant of thyroglossal duct cyst with ectodermal elements predominating (17). The acquired type was first recognized by Werhner in 1855 and was referred as implantation cyst by Sutton in 1895. The origin of acquired epidermoid cyst is believed to be implantation of epithelium into deeper mesenchymal tissues by either surgical/accidental trauma or blockage of sebaceous gland duct and sometimes even an insect bite (3,18).

Appendix Table 2: Differential diagnosis based on anatomic location of Epidermoid cyst

Lip Swelling	Lower One Third Of Face
<p>Traumatic /obstructive:</p> <ul style="list-style-type: none"> • Retention mucocele • Extravasation mucocele <p>Infection :</p> <ul style="list-style-type: none"> • Odontogenic infection: Periapical pathology • Fissural cyst : Nasolabial cyst, Globulomaxillary cyst <p>Benign tumors:</p> <ul style="list-style-type: none"> • Fibrous tissue origin : fibroma • Vascular origin: Hemangioma, AV-malformation. • Lymphatics : lymphangioma • Neural origin: Traumatic neuroma,neurilemmoma, schwannoma • Muscle origin: lieomyoma <p>Malignant tumors:</p> <ul style="list-style-type: none"> • SCC <p>Orofacial granulomatosis:</p> <ul style="list-style-type: none"> • Sarcoidosis, • Crohns disease • Tuberculosis • Leprosy <p>Others :</p> <ul style="list-style-type: none"> • Contact allergy • Hereditary angioedema 	<p>Odontogenic origin:</p> <ul style="list-style-type: none"> • Periapical pathology • Pericoronal infection • Periodontal infection • Space infection • Osteomyelitis <p>Benign tumors:</p> <ul style="list-style-type: none"> • Fibrous tissue origin : fibroma • Vascular origin: Hemangioma, AV-malformation. • Lymphatics : lymphangioma • Neural origin: Traumatic neuroma,neurilemmoma, schwannoma • Muscle origin: lieomyoma • Adipose tissue: Lipoma

In our cases, the swelling was on right lower 1/3rd of the face and in the upper lip. In these locations implantation dermoid can be considered as these sites are more prone for traumatic injuries especially during shaving. However, in our case as the past history did not reveal any traumatic episode, we assumed localized inflammation of the hair follicle or blockage of sebaceous gland duct resulted in epithelial cell proliferation producing a central mass of keratin during healing process (3,17,18).

The treatment of choice is the surgical excision either by intraoral or extraoral approach depending on the location of the EC (5). In our case, excision was done intra-orally in both the cases with a horizontal incision. This enabled direct and easy access to the cyst and also avoided the scar as the patient was esthetically concerned.

Differential diagnosis: Considering the clinical presentation in our cases such as slow growth and single, nonulcerated, well circumscribed, asymptomatic mass located within the submucosa of the cheek and upper lip, we assumed the lesions were more likely benign in nature. Infectious processes were ruled out due to absence of constitutional signs like fever, pain and an obvious foci of infection. A primary malignant process was ruled out due to the lesion's size, duration, normal surface over the mass, cystic homogeneity and lack of nodal involvement. Benign neoplastic processes which can be considered in this region may include salivary adenoma, vascular lesions, fibroma and Lipoma. Vascular lesions were ruled out as the mass failed to pulsate / blanch under pressure. In the first case, lipoma was considered as a clinical diagnosis since it was a soft and slippery sign which was positive. However, yellowish color was not appreciated because of dark skin. Minor salivary gland tumors were soft /firm masses having nodular/dome shaped elevation with smooth contours, and the overlying mucosa appeared normal/glossy because of the tension created by the underlying expanding tumor. Approximately, 75% of the minor salivary gland tumor occurs in the upper lip. Thus, salivary adenoma was considered as a clinical diagnosis in the second case. Since there is no good method of clinically differentiating salivary gland tumors from other soft tissue tumors, biopsy is mandatory for diagnosis.

Recurrence and malignant transformation:

Prognosis of EC is good with recurrence rate < 3% as reported in a recent review (19). In our cases, no recurrence was observed in the six months' follow up. A 5% rate of malignant transformation of teratoid variety of oral dermoid cyst has been reported in the literature (20).

In conclusion, epidermoid cysts of the head and neck origin are quite a rare entity. Here, we reported two case of epidermoid cyst which clinically appeared as a lipoma and salivary adenoma which later turned out to be epidermoid cyst on histopathological examination. Therefore, general health practitioners and oral health care providers should be sentient of this lesion and consider it in their differential diagnosis.

REFERENCES

1. Ozan F, Polat HB, Ay S, Goze F. Epidermoid cyst of the buccal mucosa: A case report. *J Contemp, Dent Pract* 2007;8(3):1-6.
2. Pancholi A, Raniga S, Vohra PA, Vaidya V: Midline submental epidermoid cyst: A Rare Case. *Internet J Otorhinolaryngol* 2006;4(2):1-2.
3. Kandogan T, Koc M, Vardar E, Selek E, Sezgin O: Sublingual epidermoid cyst: a case report. *J Med Case Reports* 2007; 1:87.
4. De Ponte FS, Brunelli A, Marchetti E, Bottini DJ: Sublingual epidermoid cyst. *J Craniofac Surg* 2002; 13(2):308-310.
5. Longo F, Maremonti P, Mangone GM, De Maria G, Califano L: Midline (dermoid) cysts of the floor of the mouth: report of 16 cases and review of surgical techniques. *Plast Reconstr Surg* 2003; 112:1560-1565.
6. Damle MV, Irani DK, Hiranandani NL: Epidermoid cyst of the floor of the mouth. case report. *Bombay Hosp J* 2002, 44.
7. Pereira-Santos D, De Melo WM, Brêda MA Jr, Sonoda CK, Hochuli-Vieira E. Epidermal cyst causing facial asymmetry. *J Craniofac Surg*. 2013 Mar;24(2):e112-4.
8. Phukan JP, Sinha A, Pal S, Jalan S. Cytodiagnosis of epidermoid cyst of the upperlip; A common lesion in an uncommon site. *J Lab Physicians*. 2014 Jan;6(1):60-2.
9. Dogan, Bucak IH. Congenital epidermoid cyst results in muscle fusion defect in the upperlip. *Case Rep Otolaryngol. Epub* 2014 Dec 31.

10. Wang WC, Lin LM, Shen YH, Lin YJ, Chen YK. Concurrent extravasation mucocele and epidermoid cyst of the lower lip: a case report. *Kaohsiung J Med Sci.* 2005 Oct;21(10):475-9.
11. Papanayotou PH, Kayavis JG. Epidermoid implantation cyst of the lower lip: report of case. *J Oral Surg.* 1977 Jul;35(7):585-6.
12. Ishikawa T, Morisawa N, Watanabe Y, Tanaka A, Inui H. [A case of epidermoidcyst of the lower lip region including the left mouth angle. Problems derived from the cholesterin crystals and foreign body giant cell reaction (author's transl)]. *Nihon Koku Geka Gakkai Zasshi.* 1976;22(3):406-12.
13. Sewerin I, Praetorius F. Keratin-filled pseudocysts of ducts of sebaceous glands in the vermilion border of the lip. *J Oral Pathol.* 1974;3(6):279-83.
14. Kuroyanagi K, Kawabata T, Tooi M. Epidermoid cyst of upper lip: report of a case. *Bull Tokyo dent coll.* 1973 May;14(2):95-8.
15. Shear M, Speight P: Cysts of Oral and Maxillofacial Region. 4th edition. Blackwell Munksgaard 2007: 181-3.
16. Koca H, Seckin T, Sipahi A, Kaznac A: Epidermoid cyst in the floor of the mouth: report of a case. *Quintessence Int* 2007, 38:473-477.
17. Hemaraju N, Nanda SK, Mediker SB: Sublingual dermoid cyst. *Indian Journal of Otolaryngology and Head and Neck Surgery* 2004, 3:218- 220.
18. Neville BW, Damm DD, Allen CM, Bouquot JE: Oral and maxillofacial pathology ;2rd edition W.B.Saunders Company 2002 :31-33.
19. MacNeil SD, Moxham JP . Review of floor of mouth dysontogenic cysts. *Ann Otol Rhinol Laryngol* 2010 ; 119 : 165 –73 .
20. Devine JC, Jones DC . Carcinomatous transformation of sublingual dermoid cyst: a case report. *Int J Oral Maxillofac Surg.* 2000; 29(2):126–127.