

CASE REPORT

Acanthamoeba Infection in a Drowning Child

Prastiya Indra Gunawan¹, Areta Idarto², Darto Saharso¹

ABSTRACT

BACKGROUND: *Acanthamoeba* infection is a potential life-threatening complication of drowning. The management of drowning-associated *Acanthamoeba* infection remains controversial. Survival reports on *Acanthamoeba* infection have been on case reports only.

CASE DETAILS: A 2-year-old, previously healthy Indonesian boy presented with decreased consciousness and inadequate breathing, following drowning. The event was unsupervised with unknown estimated time of submersion. Resuscitation was commenced and mechanical ventilated was applied. Sputum specimen revealed alive *Acanthamoeba* with pseudopods and cysts. Sputum culture resulted in *Pseudomonas aeruginosa* and cerebrospinal fluid was supportive for *Acanthamoeba* with 1-3 trophozoites and cyst. Imaging of the head showed cerebral edema and encephalitis. The patient received intravenous ceftazidime, metronidazole, fluconazole and rifampicin. The patient's consciousness was unsatisfactory regained resulting in an altered mental status.

CONCLUSION: No treatment so far has given a successful outcome for *Acanthamoeba*. In this case, management with metronidazole, rifampicin and fluconazole showed regain of consciousness resulting in altered mental status.

KEYWORDS: *Acanthamoeba*, Pneumonia, Encephalitis

DOI: <http://dx.doi.org/10.4314/ejhs.v26i3.12>

INTRODUCTION

Acanthamoeba infection is a life-threatening complication of drowning. A free-living protozoan, first established as a cause of human disease in the 1970s and isolated from soil, water, air, and dust, can be contracted through swimming or drowning (1,2). A case of *Acanthamoeba* infection was reported in Surabaya (2008), and two previous cases in 2002 were infected with *Acanthamoeba* spp from stagnant water (3). *Acanthamoeba* infection is known to cause three clinical syndromes: disseminated granulomatous amebic disease, central nervous system (CNS) manifestation of granulomatous amoebic encephalitis (GAE) and amoebic keratitis (1,2).

The management of drowning-associated *Acanthamoeba* infection remains controversial and there have been no recommended guidelines (4). Antimicrobial therapy for the drowning associated

pneumonia can be treated with an extended-spectrum penicillin β -lactamase inhibitor. There are four outcomes in drowning: full recovery (neurologically intact), neurological impairment, persistent vegetative state and death. While survival reports have been on case reports only (5), the purpose of this paper is to report a rare case of *Acanthamoeba* infection related to drowning event in a child.

CASE REPORT

A 2-year-old, previously healthy Indonesian boy drowned in a river and was exposed to decreased consciousness, inadequate breathing and received immediate resuscitation in Soetomo Hospital, Surabaya, Indonesia in the year 2014. Drowning even was unsupervised and the estimated submersion time was unclear.

¹Pediatric Neurology, Department of Pediatrics, College of Medicine, Airlangga University, Surabaya, Indonesia²General Pediatrician, Department of Pediatrics, College of Medicine, Airlangga University, Surabaya, Indonesia

Corresponding Author: Prastiya Indra, Email: prastiya_ig@yahoo.co.id

He presented with fever, stable hemodynamic and on the ventilator. Chest x-ray was supportive to pneumonia with granular spots. Blood and urine culture were sterile. Head Computed Tomography (CT) scan showed cerebral edema and encephalitis (Figure 1). Sputum specimen collected from the endotracheal tube showed alive *Acanthamoeba* in movements with pseudopods (Figure 2) with some transformed into cysts. Complete blood count showed white blood cell count of 21,190 cells/mcL, (Eosinophil 0.05%, Basophil 0.55%, Neutrophil 87.63%, Lymphocyte 7.98%, Monocyte 3.79%), hemoglobin of 9 g/dL, hematocrite of 27%, and platelet count of 136,500/mcL.

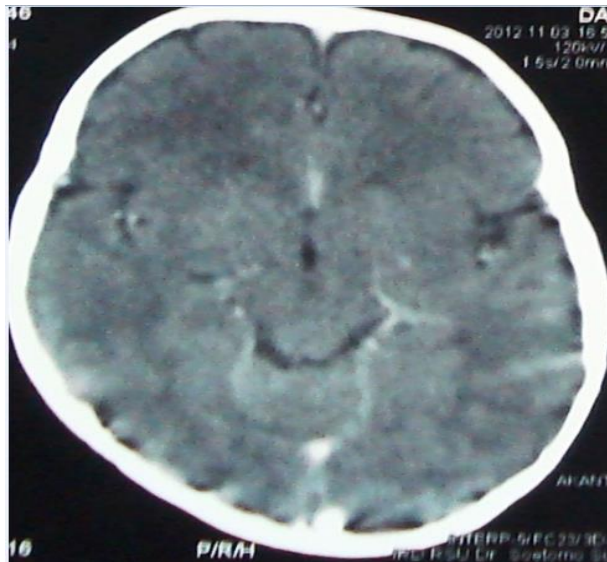

Figure 1: Head CT Scan showing cerebral edema and encephalitis

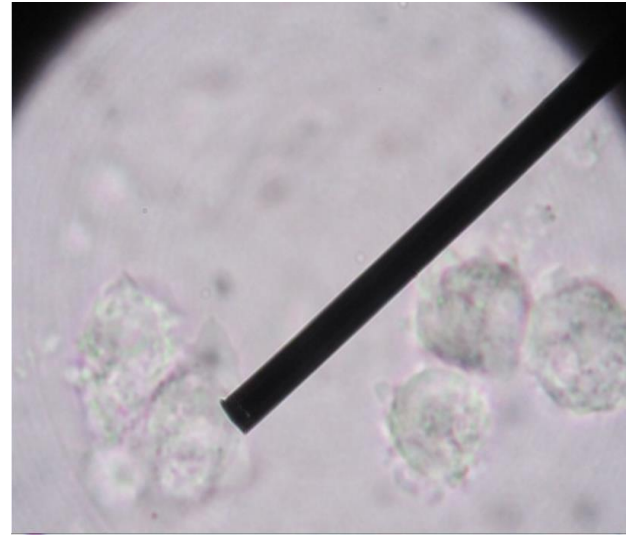


Figure 2: Sputum specimen collected from the endotracheal tube showing alive *Acanthamoeba*

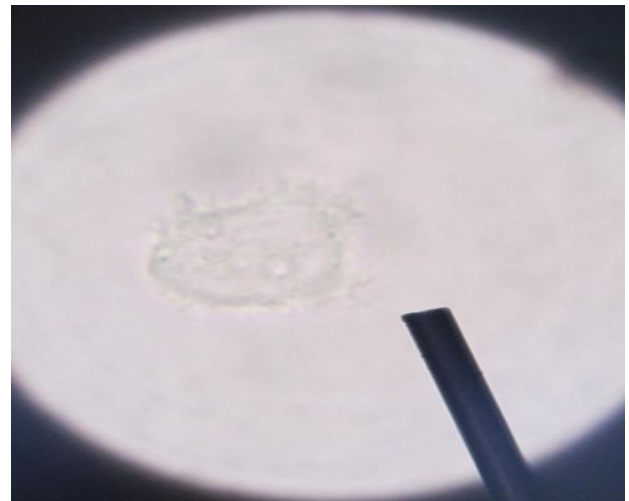


Figure 3: Fresh specimen obtained from the cerebrospinal fluid showing *Acanthamoeba*

Fresh specimen obtained from the cerebrospinal fluid was supportive for *Acanthamoeba* with 1-3 trophozoites and one cyst was seen in field view (Figure 3). Sputum culture resulted in *Pseudomonas aeruginosa*. Intravenous ceftazidime, metronidazole, fluconazole and oral rifampicin were given for three weeks, the fever subsided, without any episodes of seizure. Consciousness was regained after 7 days resulting in an altered mental status.

DISCUSSION

The WHO definition of near drowning has been replaced by drowning with either mortality, morbidity or no morbidity (6). This patient drowned in an inland, unguarded fresh water. Freshwater drowning causes hemodilution, hemolysis, hyperkalemia, hyponatremia and an elevated circulating volume, whereas seawater drowning produces hemoconcentration, hypernatremia and lower circulating blood volume. These presentations partially depend on the amount of water aspirated. Important concern in aspiration of fresh and saltwater are in regards to the impurities and bacteria contained (7-9).

The patient presented with a decrease of consciousness and compromised spontaneous breathing. Oxygen saturation and spontaneous breathing were regained on the third day of care. Leukocytosis and pneumonia were both remarkable. Individuals who experience drowning elevate the risk of pneumonia and typical oropharyngeal organisms. Most drowning victims show pulmonary symptoms and abnormal chest radiographs with fever and leukocytosis. Different agents involved depend on the type of water (7).

Pneumonia occurs in drowning event that happen within 24 hours until first weeks usually caused by aerobic gram bacteria organism (9). Sputum culture revealed *Pseudomonas aeruginosa*, sensitive to ceftazidime. *P. aeruginosa* is commonly isolated from both fresh-and seawater. Despite this water tropism, the organism is uncommonly reported to cause pneumonia after drowning (10).

Fresh sputum specimen collected from the endotracheal tube resulted in a living *Acanthamoeba* and a cyst. When *Acanthamoeba* is found on the fresh specimen, the patient had a high-grade fever with productive coughing. The following day, he developed general clonic seizure. Most drowning victims suffer from unconsciousness secondary to cerebral hypoxia. Patients who are awake and oriented upon arrival to the emergency department survive without neurologic sequelae once pulmonary problem is resolved (8).

The cerebrospinal fluid obtained from lumbar puncture was supportive for *Acanthamoeba* with 1-3 trophozoites and one cyst in field view. Improving consciousness was noted without any meningeal signs and pathological reflexes. Most patients present focal neurological deficit occurring few days to few weeks or even months after swimming, diving or drowning in stagnant fresh water. Invasive fungal disease or *Acanthamoeba* should be aggressively pursued, when patient show a slow response to antibacterial therapy, brain abscess, or meningitis.

There are two possible routes of entry to the CNS: through the nasal passage or via the blood. *Acanthamoeba* spp. are usually blood-borne. *Acanthamoeba* enters the lungs via the nasal route, traverses the lungs into the bloodstream, followed by hematogenous spread, and crosses the blood-brain barrier to enter the CNS. *Acanthamoeba* may bypass the lower respiratory tract and directly enter the bloodstream via skin lesions. The olfactory neuroepithelium provides an alternative route of entry into the CNS and has been used in experimental models (1,2,4).

Intravenous metronidazole, fluconazole and rifampicin were commenced at once. Cases of CNS involvement results in death due to inavailability of effective/recommended drugs and the drug's inability to traverse the blood-brain barrier. Current treatment involves various drugs such as fluconazole, ketoconazole, sulfadiazine, azithromycin, rifampicin and amphotericin B or itraconazole which rarely leads to a successful outcome, and depends on early diagnosis and aggressive treatment. Delivery system for the CNS drugs may include some routes. First route is trans-cranial drug delivery to the brain. Second route is trans-nasal drug delivery to the brain. Third route is transient blood-brain barrier disruption with possible complications due to side effect (1,2,9).

The ultimate prognosis in individuals with *Acanthamoeba* infection is abysmal, even with timely therapy. The disseminated disease involving CNS has a mortality rate of nearly 100%; most cases are fatal in 7-120 days (mean 39 days). Patients who remain profoundly comatose for 2-6 hours after drowning will have brain death or moderate/severe neurological impairment (5). In children who were comatose

on arrival, survival with normal brain function approximated 44%; 39% deceased, and 17% survived with brain damage.

In conclusion, early presentation of *Acanthamoeba* infection may involve encephalitis with significant deterioration of consciousness. No treatment so far has given a successful outcome. The mortality rate is high because of the unknown incubation period and treatment difficulties. In this case, management with metronidazole, rifampicin and fluconazole showed regain of consciousness resulted in altered mental status. The limitations of this report include inadequate drug availability and long term monitoring following therapy. Further study should be performed focusing on timely management and therapy.

ACKNOWLEDGEMENT

The author would thank to Mrs Nur Fitriyah for English editing.

REFERENCES

1. Siddiqui R, Khan A. Biology and pathogenesis of amoeba. *Parasites Vectors*. 2012;5:1-6. doi: 10.1186/1756-3305-5-6
2. Klivington S, White DG. *Acanthamoeba*: biology, ecology and human disease. *ClinMicrobiol Rev*. 1994;5:12-20.
3. Lestari DP, Husada D, Hidajati S. *Acanthamoeba* infection in a near-drowning child. Unpublished case report. Program PendidikanDokterSpesialisAnakFakultasKedokteranUniversitasAirlangga. 2008.
4. Shin HJ, Im K. Pathogenic free-living amoeba in Korea. *Korean J Parasitol*. 2004;42:93-119.
5. Graf WD, Cummings P, Quan L, Brutocao D. Predicting outcome in pediatric submersion victims. *Ann Emerg Med*. 1995;26:312-9.
6. Deetz TR, Sawyer MH, Billman G, Schuster FL, Visvesvara GS. Successful treatment of balamuthia amoebic encephalitis: presentation of 2 cases. *ClinInf Dis*. 2003;37:1304-12.
7. Ender PT, Dolan MJ. Pneumonia associated with near-drowning. *ClinInf Dis*. 1997;25:896-907.
8. Van Beeck EF, Branche CM, Szpilman D, Modell JH, Bierens JJ. A new definition of drowning: towards documentation and prevention of a global public health problem. *Bull World Health Organ*. 2005;83:853-6.
9. Zuckerbaun NS, Saladino RA. Pediatric drowning: current management strategies for immediate care. *Clin Ped Emerg Med*. 2005;6:49-56.
10. Chaney S, Gopalan R, Berggren RE. Pulmonary pseudallescheriabydii infection with cutaneous zygomycosis after near drowning. *South Med J*. 2004;97:683-7.